

# ASICO®

26 Plaza Drive, Westmont, IL 60559 USA  
 Phone: 1-630-986-8032 • Fax: 1-630-986-0065  
 Customer Service: 1-800-628-2879  
 www.asico.com • E-mail: info@asico.com

# Vision

# NEWS

FALL 2010

DEDICATED TO EXCELLENCE IN OPHTHALMOLOGY

## What is your Toric instrument choice?

Pre-Op

Intra-Op Single Hand

Intra-Op Two Hand



**AE-2793S:** Pre-Op Toric Reference Marker, Single-Side



**AE-2794:** Intra-Op Toric Axis Marker II



**AE-2798N:** Graether Half Circle Axis and Capsulorrhexis Reference Marker


**AE-1594N:** Graether Degree Gauge



**AE-2791TBL:** Nuijts/Lane Pre-Op Toric Reference Marker with Bubble Level




**AE-2848N:** Modi Low Profile Intra-Op Toric Marker



**AE-2740H:** Nuijts Toric Axis Marker with 5mm Center Opening and Centering Device

**AE-1592N:** Yeoh Thin Toric Gauge 14mm/12mm



**AE-2740N:** Nuijts-Solomon Toric Axis Marker with 5mm Center Opening

**AE-1590T:** ASICO Beveled Degree Gauge, Titanium

## Femtosecond: A New Era in Cataract Surgery




**Dr. Stephen Slade**  
Houston, TX

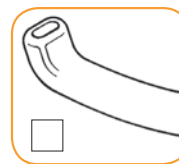
Stephen G. Slade MD, FACS is confident that femtosecond laser cataract surgery will be a significant advantage for difficult cataract cases in the future. Dr. Slade has been using the technique in his practice in Houston since February of this year, 2010. Patients who have traumatic cataracts, dislocated lenses or zonular dehiscence would very likely benefit from femtosecond laser cataract surgery. The “no touch” capsulorrhexis technique is safer to perform in cases with compromised zonules and the laser “pre-chopping” of the nucleus allows for faster phacoemulsification at a reduced power. Dr. Slade’s results also show a reduction in endothelial cell loss compared to manual phacoemulsification, key for cases such as Fuch’s Dystrophy. In addition, Dr. Slade believes that cases involving

pseudoexfoliation, thickened or scarred capsules, and white cataracts would profit from the precision and flexibility of femtosecond laser cataract surgery.

Several new ASICO products have proved extremely helpful in femtosecond cataract surgery, such as the Slade spatula, which is designed with a flat tip. This is used to open the main and side port incision made by laser machine. In laser cataract surgery, the surgeon identifies and opens, rather than creates, the incisions. The new Slade Hydrodissection Cannula is useful as well. The Femtosecond laser, while emulsifying the nucleus, produces gas bubbles beneath the nucleus and changes the dynamics of traditional hydrodissection. The new hydrodissection cannula helps to release the gas bubble trapped beneath the nucleus and thus helps create a more efficient hydrodissection.



**AE-2326:** Slade Femtosecond Spatula



**AE-7654:** Slade Femtosecond Hydrodissection Cannula

For our entire selection,  
please visit  
[www.asico.com](http://www.asico.com)

### In this issue...

- + DMEK: Useful techniques ..... P2
- + Consistent Big Bubble and DSAEK Choices .... P3
- + Today's Glaucoma and Perfect Partners for ICL . P4
- + LRI Options ..... P4
- + Microcoaxial Made Easy ..... P5
- + VR by ASICO..... P6

# DMEK:

## Descemet's Membrane Automated Endothelial Keratoplasty

by Dr. Charles Ahn

Although Descemet's membrane automated endothelial keratoplasty (DSAEK) has gained much success recently, Descemet's membrane endothelial keratoplasty (DMEK) is rapidly proving to show much promise for both patients and surgeons as a better alternative.

DMEK is the latest version of endothelial keratoplasty. The difference between DMEK and DSAEK is that Descemet's membrane without any stroma is harvested and transplanted in DMEK.

There are several potential advantages of DMEK over DSAEK. Advantages include superior visual outcomes, quicker recovery, use of inexpensive techniques, increased availability of tissue, and decreased crowding of the anterior chamber. Surgeons such as Dr. Francis Price, Dr. Melles, and Dr. Giebel have reported outstanding outcomes with DMEK when compared to DSAEK. I have also experienced these advantages of DMEK over DSAEK with my patients in my practice. 9 of my first 10 DMEK patients underwent successful transplantation with 8 of the 10 patients achieving a best corrected visual acuity of 20/40 or better within the first 3 months. In addition, 5 of the 9 patients undergoing successful DMEK had a best corrected visual acuity of 20/25 or better at 3 months.

DMEK is the next step in the progression of surgical treatment for endothelial disease. Transplantation of the Descemet's membrane with the absence of stroma is what sets DMEK apart from the other endothelial keratoplasties. The advantages of this procedure have convinced me to consider DMEK as not only an alternative surgical treatment for DSAEK, but a replacement for my patients.

This surgery involves new skills and techniques. The success of the surgery depends on reliable harvesting of the graft, intraocular placement and positioning of the graft, and complete attachment of the graft in the postoperative period. There is certainly a learning curve for DMEK, but the results indicate the investment of time will be well worth the effort.



**Dr. Charles Ahn**  
Downers Grove, IL



**AE-2327:**  
Ahn DMEK Rake



**AE-7002:**  
Ahn DMEK Cannula, 23g

# DMEK:

## A Useful Technique

by Dr. Thomas John

Compared to DSAEK, Descemet's membrane endothelial keratoplasty (DMEK) is a much more effective way in eliminating surgically induced hyperopia and significantly improving quality of vision when it comes to selective tissue corneal transplantation (STCT). While DSAEK is a "tissue-addition" procedure, DMEK is a "tissue-substitution" focused procedure and is my preferred technique.

When using the DMEK technique, I find many of ASICO's products useful in performing STCT surgery. For instance, the John DMEK instrument set is extremely effective and includes items such as the John DMEK/DSAEK Dextatome Spatula (AE-2872), John DMEK Twin-Block (AE-1586), John DMEK 30g Cannula (AE-7003), and the John DMEK Small and Large Crystal Spatula (AE-2328, AE-2329).

When performing the DMEK procedure, there are some key points to keep in mind:

- Tissue handling is of paramount importance. The goal is to minimize the amount of iatrogenic endothelial cell loss. Least amount of endothelial cell loss is the goal.
- Unfold Descemet's membrane (DM) with proper orientation. Tissue staining with trypan blue is essential.
- Avoid flipping the DM in the wrong direction (i.e. endothelium facing patient's corneal stroma)
- Ensure peripheral Iridectomy is full-thickness.
- Use a "big-bubble" technique to attach the DM (large air-bubble).
- Remove epithelium if needed to optimize visualization of the anterior chamber.

Most importantly, there are many advantages to using DMEK. It is a major cost saving procedure compared to DSAEK, there is no need for any type of glide and no artificial anterior chamber is required. In addition, no pre-cut tissue from the eye bank is needed and you do not need an expensive microkeratome. DMEK usually restores vision faster than DSAEK.



**Dr. Thomas John**  
Chicago, IL



**AE-1586:** John DMEK Twin Block




**AE-2328:**  
John DMEK Large  
Crystal Spatula

**AE-2329:**  
John DMEK Small  
Crystal Spatula

Available in Large and Small



**AE-7003:** John DMEK Cannula, 30g



**AE-2872:** John DMEK/DSAEK  
Dextatome Spatula

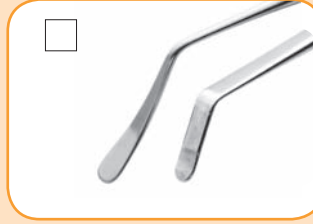# Consistent Big Bubble



**Dr. Thomas John**  
Chicago, IL



**AE-2849:**  
John ALK Marker  
• 8 radial marks for the 8-interrupted nylon sutures




**AE-2902:**  
John ALK  
Pre-Descemet's spatula  
• Double ended instrument effectively and safely dissects the corneal stroma adjacent to recipient DM without any significant added risk of tearing DM



**AE-7824:**  
John ALK cannula  
27g, 3 holes  
• Triple port cannula provides larger area of air release with a more diffuse stromal dissection




**Dr. Vincenzo Sarnicola**  
Grosseto, Italy



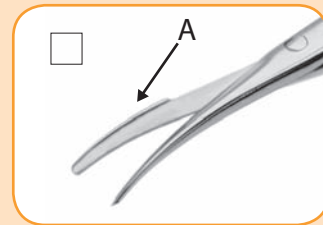
**AE-2900:**  
Sarnicola Big bubble Spatula  
• Highly polished spatula helps to create an inter-corneal tunnel and avoids penetrating the DM



**Dr. Donald Tan**  
Singapore



**AE-7803:**  
Tan DALK Cannula 27g  
• Tip is blunt and smooth to prevent inadvertent perforation of DM



**AE-5666/AE-5667:**  
Tan DALK scissors Right/Left  
• Unique safety platform on lower tine (A) ensures blades are well separated from DM when cutting stroma

# DSAEK Choices



**AE-2868:**  
Kobayashi DSAEK Marker  
• Marks in dots along the circumference and prevents ink from running so visibility is clear throughout the procedure




**AE-4219:**  
Villarrubia DSAEK Forceps  
• Forceps are designed to grab (using .12 bonn style tips) the donor button on the stromal side only, reducing endothelial damage



**AE-4226:**  
Tan DSAEK Forceps  
• Safely and effectively inserts the donor button with the pull-through technique


# For Today's Glaucoma Procedure




**AE-1526:**  
Crandall USC Marker  
• Two-in-one marker, designed to mark the sclera with an outer pattern of 5.00mm by 5.00mm and inner pattern of 4.00mm by 5.00mm (triangle)



**AE-8114:**  
Micro Crescent Diamond Knife  
• Ideal for dissecting the initial and second flap, the blade width is 1.2mm



**AE-2430:**  
Crandall USC Scleral Planar  
• Scleral Planar 1.0mm in width with dual cutting edges to rapidly remove layers of sclera in either direction



**AE-2431:**  
Crandall USC Scleral Shaver  
• Angled instrument with a sharp edge designed to remove layers of sclera



**AE-8304:**  
Kitahara Rotatable Glaucoma Punch  
• Square 1.0mm x 1.0mm tip easily removes tissue from trabecular meshwork with a rotating mechanism that cuts are rectangular shape all around without any uneven edges

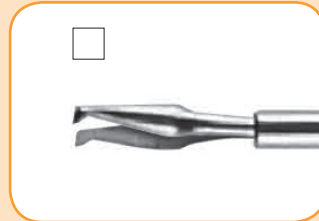# Perfect Partners for ICL



**AE-8149:**  
Zaldivar (Zap II) Diamond Knife  
• 10 facet blade designed for anterior surgical procedures including implanting of ICLs and others



**AE-4446N:**  
Zaldivar-Kraff ICL PACman Forceps  
• Features specifically designed jaws with atraumatic ridges to grasp ICL without damage




**AE-4965:**  
Zaldivar Iridectomy Forceps  
• 23g instrument with a 90° tip which has specially designed jaws to enclave the iris to the IOL



**AE-5665:**  
Zaldivar Iridectomy Scissors  
• 20g instrument with curved blades of scissors for ease of cutting and better visualization

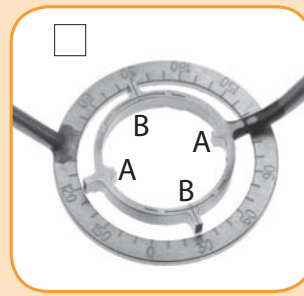
# LRI - Options



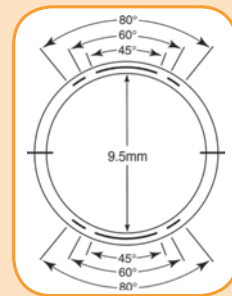
**AE-8122:**  
Koch Double Foot Plate LRI Diamond Knife  
0.50-0.55-0.60mm  
• Double foot plate ensures consistent wound architecture



**AE-8187:**  
3 Settings LRI Diamond Knife  
0.50-0.55-0.60mm  
• Single foot plate for better visualization



**AE-2863:**  
Koch LRI Axis Marker in Degree  
• Reference marks (A) at 0° and 180°



**AE-2764N:**  
Zaldivar Fixation Ring and Degree Gauge (Superior)  
• Designed with an axis extension (B) to easily align with the steepest meridian while working with a degree gauge for precise alignment

# Microcoaxial Made Easy



## 1 Incision Decision

### ADVANCUT Clear Corneal Angle Blades



AS-8312 - 2.0 mm  
AS-8313 - 2.2 mm  
AS-8315 - 2.4 mm  
AS-8316 - 2.5 mm

### Diamond Knives




AE-8190:  
Akahoshi Ultra Diamond Knife  
• Trapezoidal blade of 2.0mm at the shoulder and 2.3 mm at the base

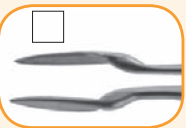


AE-8192:  
Akahoshi Nano Diamond Knife  
• Trapezoidal blade of 1.7mm at the shoulder and 2.0mm at the base

## 4 Prechoppers



AE-4190:  
Akahoshi Combo II Prechopper  
• Designed for prechopping soft nuclei grades 1 and 2



AE-4192:  
Akahoshi Universal II Prechopper  
• Designed for prechopping hard nuclei

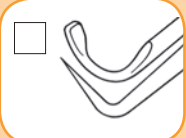


AE-4293:  
Inamura Eagle Prechopper  
• The shape of the tip makes rotation of the nucleus easier in the capsule bag



AE-4286:  
Akahoshi Hybrid Combo Pre Chopper  
• Groove enables easy rotation of the nuclei during prechopping

## 5 Choppers



AE-2573:  
Chang DUO Quick Chopper

- Sharp vertical tip ideal for incising brunescant nuclei
- Modified "Microfinger" for chopping on other end

## 2 Capsulorrhexis



AE-4402:  
Ikeda Nozomi  
Capsulorrhexis Forceps

- 45° tip has unique design like Japan's Shinkansen Super Express train to maximize visibility



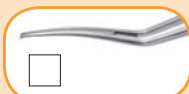AE-4385N:  
Ikeda Super Micro  
Capsulorrhexis Forceps

- 90° curved forceps allow for easy maneuverability through the paracentesis incision



AE-4344:  
Akahoshi  
Capsulorrhexis Forceps

- 11mm long blades with very thin profile manipulates easily through an incision size as small as 1.8mm (Flat Handle)



AE-4344V:  
Tjia-Akahoshi  
Capsulorrhexis Forceps

- Vaulted jaws to contour to the shape of the anterior capsule (Flat Handle)



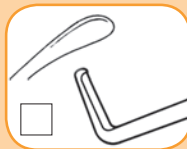AE-4503RH:  
Kraff-Utrata Capsulorrhexis  
Forceps with Sharp Tip and  
Laser Lines

- Thin profile fits through a 2.2mm incision and reduces visco loss when jaws open and close (Round Handle)



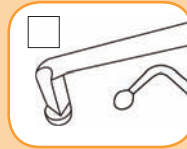
AE-4504RH:  
Kraff-Utrata Capsulorrhexis  
Forceps, with Vault and  
Laser Lines

- Vaulted jaws to contour to the shape of the anterior capsule (Round handle)



AE-2520:  
Nagahara Chopper and  
Koch Spatula

- 60° Nagahara on one end to chop towards phaco handpiece
- Koch spatula pushes, lifts, rotates, and dissects



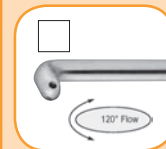
AE-2546:  
Lubeck Horizontal Chopper  
and Nucleus Sustainer

- Nagahara Chopper (AE-2517) on the other end: horizontal chopper with 60° cutting edge
- Akahoshi Nucleus Sustainer (AE-2530) on other end: 0.4mm ball tip for atraumatic handling and support, can also be used to chop soft nuclei

## 3 Hydrodissection



AE-7642:  
Inamura II Hydrodissection  
Cannula 22g Sandblasted  
• 45° angled flow for efficient hydrodissection



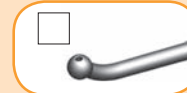AE-7643:  
Miyoshi Ultimate Vertical Dual  
Flow Hydrodissection Cannula 23g  
• 120° angled flow allows complete hydrodissection in both the anterior and posterior capsule simultaneously

## 6 I/A



AE7-3052: Akahoshi  
Mini Curved I/A Tip

- S-curve shape enables the instrument to maneuver easily along the fornix



\*AE7-3061: Akahoshi  
Bent Ball I/A Tip

- Ball shape maximizes aspiration with less movement

\*Sandblast Options Available

## 7 Injector



AE-9036SP:  
ASICO Royale III Injector

- Single handed spring injector designed for Alcon Monarch\* B, C, and D cartridges

\*Trademark of Alcon

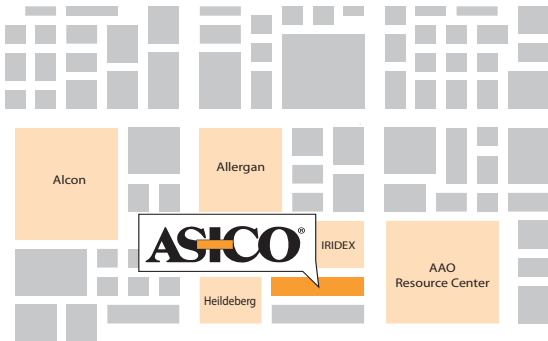# ASICO®

26 Plaza Drive  
Westmont, Illinois 60559  
U.S.A

First Class  
US Postage  
**PAID**  
Downers Grove, IL  
Permit # 163

**AAO**  
Chicago  
2010

**Booth # 2636-2641**



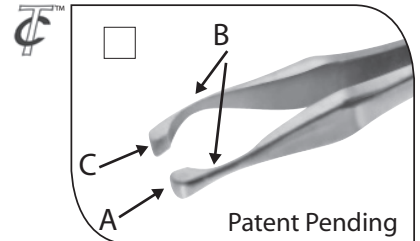
Tired of waiting? Pre-order today and avoid long lines.  
Call 1-630-986-8032 or Email [info@asico.com](mailto:info@asico.com) for more details!

## VR by ASICO®

### Latest Instruments for 23, 25, 27g (T=Thin)

#### VRTIS™ Thin Corcostegui Forceps 23, 25g: AE-4913T/AE-4925T

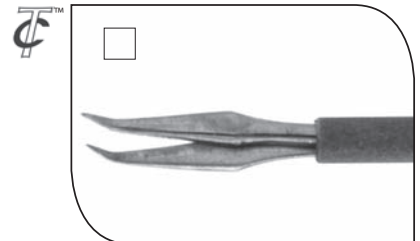
- Jaws of forceps can be used as a Pick (A) and a Spatula
- Concave tips (B) for maximum visibility
- Broad surface (C) enables secure holding of membrane for efficient peeling
- Dr. Corcostegui Recommends:
  - Thinner version (AE-4913T 23g, AE-4925T 25g) for peeling smaller surface with less adhesion
  - Regular version (AE-4913 23g, AE-4925 25g, AE-4915 27g) for peeling large surface area with strong adhesion



Patent Pending

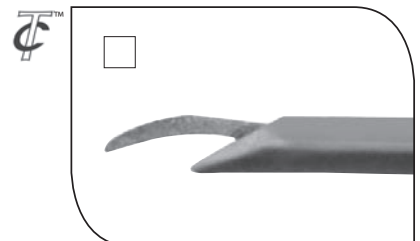
#### VRTIS™ Ohji Horizontal Scissors 23g, 25g: AE-5607/AE-5680

- Rounded tip acts as a pick to lift the membrane and scissors to cut along the retinal surface
- Curvature of tips similar to horizontal scissors follows the retinal surface
- Unique tip curvature suitable for easy entry into sub membrane space



#### VRTIS™ Kusaka Vertical Scissors 23g: AE-5609

- Unlike conventional vertical scissors, these scissors feature atraumatic tips on the moving and fixed blade allowing easy and atraumatic insertion into space between retina and fibro vascular membrane
- Ideal for dissecting and secure peeling of fibro vascular membrane even in diabetic retinopathy



Trocar Compatible

